

Revised Abstract

Background: *Candida* spp. remain a common cause of mucosal and invasive candidiasis. On occasion, patients develop refractory candidiasis due to either secondary resistance to antifungals or due to innate immune system deficiencies. Ibrexafungerp (IBX) is a novel orally-bioavailable antifungal (glucan synthase inhibitor) that has documented broad spectrum of activity against the most common *Candida*, *Aspergillus*, and *Pneumocystis* spp. We report a case of severe refractory esophageal candidiasis (EC) that was successfully treated with IBX.

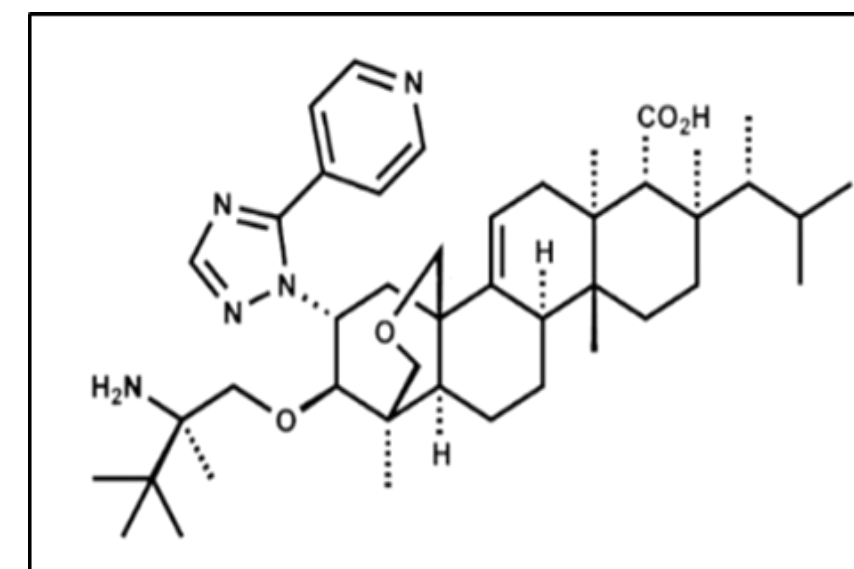
Materials/methods: A 63 year old man with documented EC, refractory to fluconazole 200mg per day, was enrolled into an open-labeled clinical trial, Scynexis Study 301 (FURI) (clinicaltrials.gov identifier- NCT03059992). The study evaluated the efficacy and safety of IBX in patients intolerant or refractory to antifungal therapy. The patient's past medical history included 10 yrs of esophageal strictures with recurrent EC. Recently, the dysphagia had become so severe, that he was unable to swallow and thus had a feeding tube inserted. A recent esophagogastroduodenoscopy (EGD) demonstrated severe EC throughout the esophagus. A culture revealed *Candida glabrata* resistant to fluconazole (MIC 256 µg/ml). After informed consent was signed, the patient was enrolled, and treated with IBX. The patient was given a loading dose, oral IBX 750 mg twice a day x 2 days, followed by oral IBX 750 mg daily for a total of 54 days.

Results: During IBX therapy, the patient gradually improved and by day 54 he was completely asymptomatic. The only reported adverse event was mild lower extremity edema during therapy. One month after discontinuing therapy, the patient remained asymptomatic and he was able to eat and drink without discomfort. A repeat EGD did not demonstrate any EC. Two months later, the feeding tube was taken out. At the nine month follow up, the patient remains asymptomatic and continues to gain weight.

Conclusions: This report demonstrates the efficacy of IBX in a patient with severe recalcitrant and refractory EC, and highlights the potential for using IBX to manage difficult to treat azole resistant and refractory candidiasis. The FURI study will continue to enroll more subjects to evaluate the safety and efficacy of IBX.

BACKGROUND

Candida species remain a common cause of mucosal and invasive candidiasis. On occasion, patients develop refractory candidiasis due to either secondary resistance to antifungals or due to innate immune system deficiencies. Ibrexafungerp (IBX) (formerly SCY-078) is a novel orally-bioavailable antifungal (glucan synthase inhibitor) that has documented broad spectrum of activity against the most common *Candida*, *Aspergillus* and *Pneumocystis* spp. Currently, oral ibrexafungerp is in clinical development for the treatment of invasive aspergillosis, vulvovaginal candidiasis and refractory fungal infections.



Ibrexafungerp (IBX): a novel triterpenoid

Ibrexafungerp has demonstrated an extensive tissue distribution and achieves tissue exposures that are often greater than blood. Specifically, a mass balance study in rats using [¹⁴C] labeled ibrexafungerp showed that the exposures achieved in esophagus are >6 fold higher than blood, supporting the potential clinical utility in the treatment of esophageal infections (S Wring, et al. 2019. AAC 63:e02119-18).

SCYNEXIS initiated an open-label study to evaluate the efficacy and safety of ibrexafungerp in patients with invasive fungal infections that are refractory to or intolerant of standard antifungal treatment (FURI) (Clinicaltrials.gov NCT03059992), including mucocutaneous and invasive candidiasis. We report a case of severe refractory esophageal candidiasis (EC) from the FURI study, that was successfully treated with ibrexafungerp.

METHODS

Case Study: A 63 y/o man with documented EC, refractory to fluconazole 200 mg per day, was enrolled into the FURI study at Augusta University, Augusta, GA. The patient's past medical history included 10 years of esophageal strictures with recurrent EC. Recently, the dysphagia had become so severe, that he was unable to swallow and thus had a feeding tube inserted. A recent esophagogastroduodenoscopy (EGD) demonstrated severe EC throughout the esophagus. A culture revealed *Candida glabrata* resistant to fluconazole (256 µg/ml), voriconazole (4 µg/ml) and posaconazole (> 8 µg/ml). After informed consent was signed, the patient was enrolled, and treated with IBX. The patient was given a loading dose, oral IBX 750 mg twice a day x 2 days, followed by oral IBX 750 mg daily for a total of 54 days.

RESULTS

Case Study

During IBX therapy, the patient gradually improved and by day 54 he was completely asymptomatic, the EGD showed no evidence of EC and the IBX treatment was considered completed (end of therapy, EOT). The only adverse event reported was mild lower extremity edema. At his follow up visit (~ 6 weeks after EOT) the patient remained asymptomatic and he was able to eat and drink without discomfort. A repeat EGD did not demonstrate any EC. Two months later, the feeding tube was taken out. At nine months after completion of IBX therapy the patient remained asymptomatic.

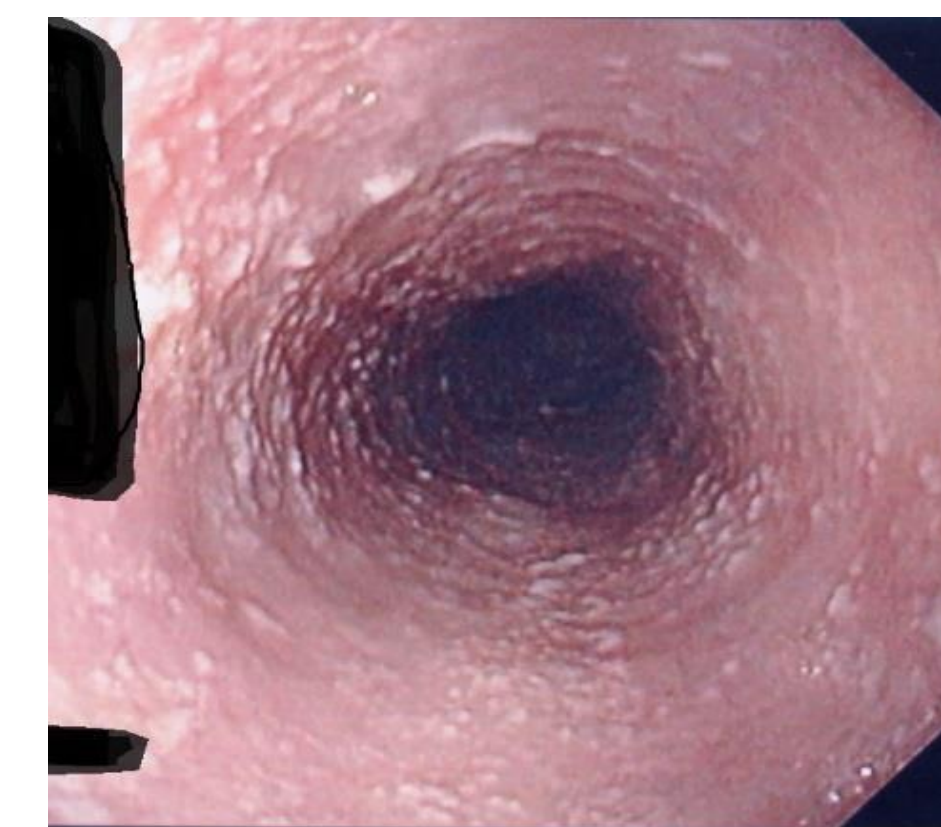


Figure A: EGD pre-therapy

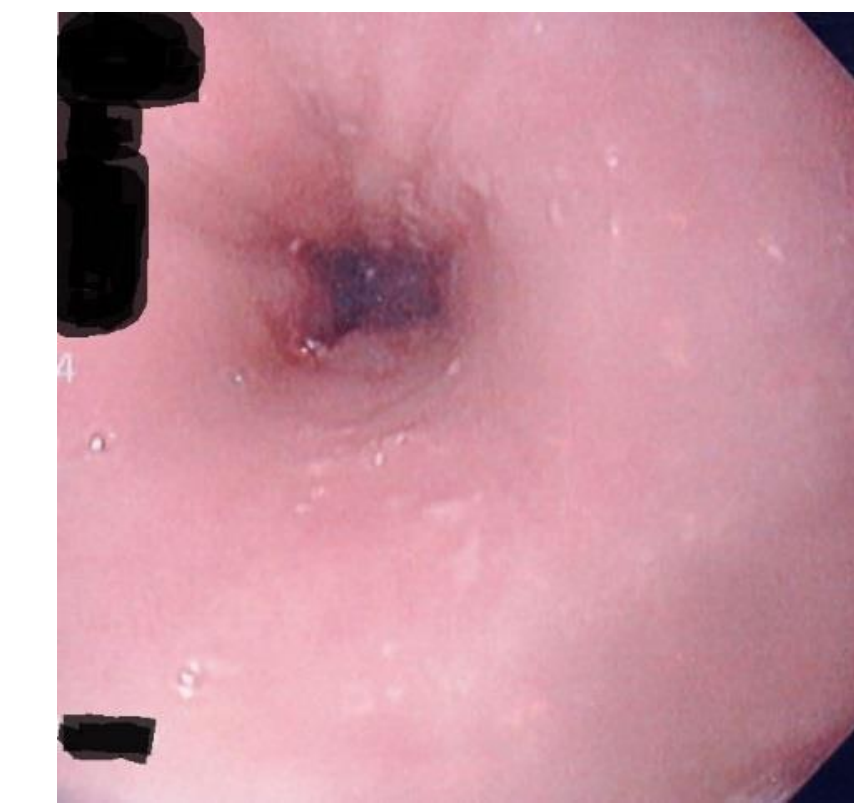


Figure B: EGD 2 months after IBX EOT

Drug	Baseline Isolate <i>C. glabrata</i> MIC (ug/ml)
5-FC	< 0.06
Amphotericin B	1
Anidulafungin	0.030
Caspofungin	0.030
Micafungin	< 0.008
Fluconazole	256
Posaconazole	> 8
Voriconazole	4

FURI Study Outcomes

Additionally, an independent Data Review Committee (DRC) provided an assessment of treatment response for 20 patients who completed therapy in the FURI study. Patients were enrolled in 14 centers from 4 countries. The global outcome for the 20 patients analyzed in the FURI study by the DRC was as follows: complete/partial response 11(55%), stable disease 6 (30%), progression of disease 2 (10%) and indeterminate 1(5%). Among these 20 cases assessed, there were 9 cases of mucocutaneous candidiasis enrolled in the study including, esophageal candidiasis (6), oropharyngeal candidiasis (3) and chronic mucocutaneous candidiasis (1) with outcomes as follows: complete/partial response 6 (55%), stable disease 3(30%), progression of disease 1(10%).

Table 1: Patient outcomes as determined by DRC for all patients and patients with mucocutaneous candidiasis

	Complete/Partial Response	Stable Disease	Progression of Disease	Indeterminate
All Patients (20)	11 (55%)	6 (30%)	2 (10%)	1
Mucocutaneous Candidiasis (9)	5 (55%)	3 (30%)	1 (10%)	

CONCLUSIONS

This report illustrates the efficacy of IBX in a patient with severe recalcitrant, refractory and multidrug-resistant *Candida glabrata* esophageal candidiasis and highlights the potential for using IBX to manage difficult to treat azole-resistant and refractory candidiasis. The FURI study will continue to enroll more subjects to evaluate the safety and efficacy of IBX in these difficult to treat infections.